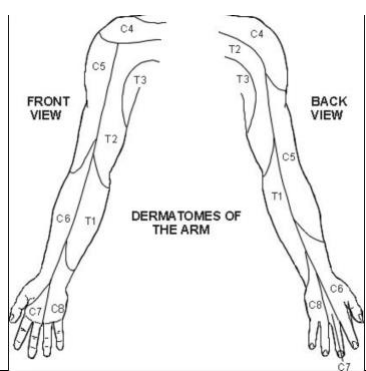


Elbow Exam

GLOBAL MARK			
CLEAR PASS	BORDERLINE PASS	BORDERLINE FAIL	FAIL

Criteria

Introduces Self, confirms patient identify, Washes hands,	2, 1
Offers analgesia, ensures comfort of patient	2
Offers chaperone	
Patient exposed – from shoulder to fingers	
<p>Inspects</p> <ul style="list-style-type: none"> Shoulder, humerus, elbow and forearm Erythema Scars + Deformity 	
<p>Palpates</p> <ul style="list-style-type: none"> Down humerus, checking both epicondyles, olecranon and radial head. 	
<p>Sensation</p>  <ul style="list-style-type: none"> C5 – back of arm C6 – thenar eminence C7 – middle finger C8 – ulnar portion of hand T1 – medial forearm <ul style="list-style-type: none"> Radial N posterior asp 1st webspace Median radial border of index Ulnar – ulnar border little finger 	
Checks distal pulses	
<p>Moves</p> <ul style="list-style-type: none"> Active and Passive Flexion 145 Pronation 75, Supination 80 	
Summarises findings	
Management plan	
Thanks patient	