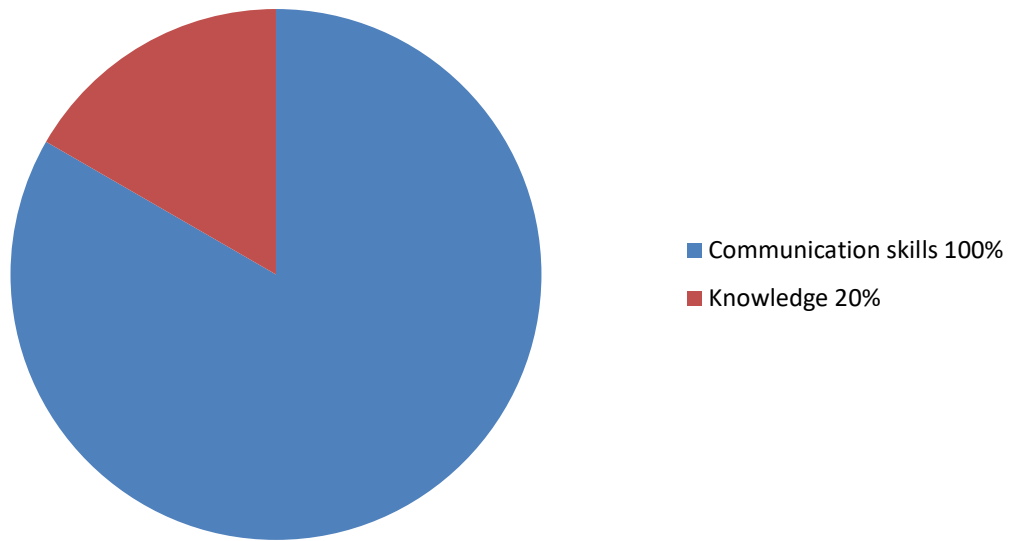


## Marking



The father of a 6 year old child has been called to return to the ED as the child has had a greenstick fracture of the distal radius missed by an SHO. The nurse assisting you states that the father is very angry

Washed hands	
Introduces self	
Checked identity of relative	
Re-iterates why patient has been re-called	
Allows father to air his grievances	
If child present offers analgesia	
Acknowledges fathers concerns	
Apologises that the fracture was missed	
Explains that many juniors and all x-ray reviewed by x-ray specialists	
Explains that the delay in treatment will not cause any long term damage	
Offers to show parent image	
Outlines treatment required now	
asks about any other concerns – PALS if necessary	
That's patient for the time and understanding	
Patient global score	

Anna Beyston 2019